



The parietal cortex and episodic memory: an attentional account

Roberto Cabeza*, Elisa Ciaramelli†, Ingrid R. Olson§ and Morris Moscovitch¶||

Abstract | The contribution of the parietal cortex to episodic memory is a fascinating scientific puzzle. On the one hand, parietal lesions do not normally yield severe episodic-memory deficits; on the other hand, parietal activations are seen frequently in functional-neuroimaging studies of episodic memory. A review of these two categories of evidence suggests that the answer to the puzzle requires us to distinguish between the contributions of dorsal and ventral parietal regions and between the influence of top-down and bottom-up attention on memory.

Episodic memory

Memory for personally experienced past events.

Medial temporal lobe

(MTL). A brain area that contains several structures that are critical for declarative-memory function, such as the hippocampus and the parahippocampal gyrus.

If 20 years ago a neurologist had been asked whether the parietal cortex played an important part in episodic memory, the answer probably would have been negative. Such an answer would have been quite reasonable given that parietal lesions do not yield severe episodic-memory deficits, such as those that are associated with damage to the medial temporal lobe (MTL). During the past two decades, however, numerous studies using event-related potentials (ERPs)¹, positron-emission tomography (PET) and functional MRI (fMRI)² have shown that the parietal cortex is one of the regions that is most frequently activated during episodic-memory retrieval. Thus, the contribution of parietal regions to episodic memory constitutes an intriguing scientific puzzle. Potential answers have begun to emerge only recently. First, the development of event-related fMRI methods has allowed imaging researchers to specify the types of memory processes that are associated with activations in different parietal subregions. Second, a few neuropsychological studies have demonstrated that parietal lesions do impair certain episodic-memory processes. Finally, memory researchers have started focusing on the contributions of the parietal cortex, and have proposed several hypotheses with clear, testable predictions. As a result, a new domain of cognitive-neuroscience research has emerged with a critical mass of empirical evidence and a set of testable hypotheses.

The goal of this Review is to provide a concise overview of this new domain of inquiry. The article is intended for the general neuroscience audience; more detailed reviews intended for memory experts can be found in other related publications^{3,4}. We begin by summarizing accepted ideas regarding the anatomy and function of the parietal cortex. This is followed

by a review of recent findings from neuropsychology and neuroimaging studies that link parietal function to episodic retrieval. Next we review the potential explanations for these findings and discuss our attention-based hypothesis. We end by considering several open questions about the contribution of the parietal lobe to episodic memory.

Anatomy and functions of the parietal cortex

The parietal cortex includes a strip posterior to the central sulcus that is specialized for somatosensory function (Brodmann areas (BAs) 1, 2, 3 and 5), as well as regions posterior to this strip that are known as the posterior parietal cortex. These posterior regions can be grossly divided into a medial and a lateral portion. The medial posterior parietal lobe consists primarily of the precuneus. The precuneus is sometimes considered together with posterior cingulate and retrosplenial regions, which are areas where lesions can produce amnesia⁵⁻⁷. However, posterior cingulate and retrosplenial cortices are not parietal regions, and hence they are not discussed in this Review. The posterior parietal cortex can also be divided into the dorsal and ventral regions (usually known as the dorsal and ventral parietal cortex, respectively). The dorsal parietal cortex (DPC) includes the lateral cortex in the banks of the intraparietal sulcus (IPS) and the superior parietal lobule, as well as the precuneus. The ventral parietal cortex (VPC) includes lateral cortices that lie ventral to the IPS, including the supramarginal gyrus and the angular gyrus (FIG. 1a). The DPC roughly corresponds to the lateral and medial parts of BA7, whereas the VPC roughly corresponds to BAs 39 and 40 (typically called the inferior parietal lobe).

*Center for Cognitive Neuroscience, Duke University, B203 LSRC building, Durham, North Carolina 27708, USA.

†Rotman Research Institute, Baycrest centre, 3560 Bathurst Street, Toronto, Ontario M6A 2E1, Canada.

§Department of Psychology, Temple University, 1701 North 13th Street, Philadelphia, Pennsylvania 19122, USA.

¶Department of Psychology, University of Toronto, 100 Saint George Street, Toronto, Ontario M5S 3G3, Canada. Correspondence to R.C. e-mail: cabeza@duke.edu doi:10.1038/nrn2459

As illustrated by FIG. 1b, the lateral parietal cortex has direct anatomical connections with many brain regions, including the dorsolateral prefrontal cortex^{8–11}, the temporal cortex¹² and medial parietal^{13,14} regions. It also has reciprocal connections with entorhinal,

parahippocampal and hippocampal regions of the MTL^{15–21}. Analysing spontaneous fluctuations in the fMRI bold signal²² revealed that the human hippocampal formation has strong functional connections with the VPC. As we discuss later, this evidence supports the idea that the VPC processes memory information in the same way that it processes sensory information.

Traditionally the lateral parietal cortex was thought not to support episodic memory, but rather to be implicated in attention to spatial information, movement planning and control, multisensory integration and working memory^{23–26}. Indeed, unilateral lesions in the inferior parietal cortex often result in hemispatial neglect^{27–30}. Patients with neglect fail to report or respond spontaneously to stimuli in the contralesional hemifield^{30,31}, but they can rely on top-down mechanisms to voluntarily direct attention or action towards locations in any region of space³². Bilateral parietal lobe damage can lead to partial or full-blown Balint's syndrome³³, including simultanagnosia, the inability to perceive or attend to more than one visual object or location at a time. However, these lesions do not lead to amnesia.

Parietal lesions and episodic memory

Because patients with parietal lobe damage do not show retrograde or anterograde amnesia, few investigators have assessed memory in these patients. Thus, subtle episodic-memory deficits may have been overlooked. A recent study of the effects of parietal lobe damage on autobiographical memory and episodic memory supports this³⁴. Patients with parietal lesions that were mostly in the VPC (FIG. 2a), along with matched controls, were required to recollect various autobiographical memories. In the first phase, the participants freely recalled events from their lifetime in as much detail as possible. In a second phase, they answered specific questions about the recalled memories. The results showed that parietal lobe damage decreased the vividness and amount of detail freely recalled (similar results were obtained in patients with unilateral lesions³⁵). However, when patients were questioned for specific details pertaining to their memories, they performed normally³⁴ (FIG. 2b). This memory deficit was not restricted to spatial aspects of memories. Rather, deficits generalized to perceptual, emotional and referential details. Because this task did not require encoding, the patients' impoverished performance is best characterized as a memory-retrieval deficit.

In another study, patients with left and right VPC lesions (FIG. 2c) and normal controls took part in a source-memory test³⁵. Participants heard pairs of stimuli, read by a female or a male voice. Later they were required to recall and recognize the item that had been associated with each stimulus, and to determine its source (male versus female voice). Last, for each recognized pair, participants had to judge whether recognition of the pair elicited recollection or familiarity. Recollection refers to a sense of reliving the encoding context vividly, whereas familiarity refers to a sense that the event happened in the past, but without any information as to the circumstances and context of its occurrence³⁶. The results showed no impairment in cued recall,

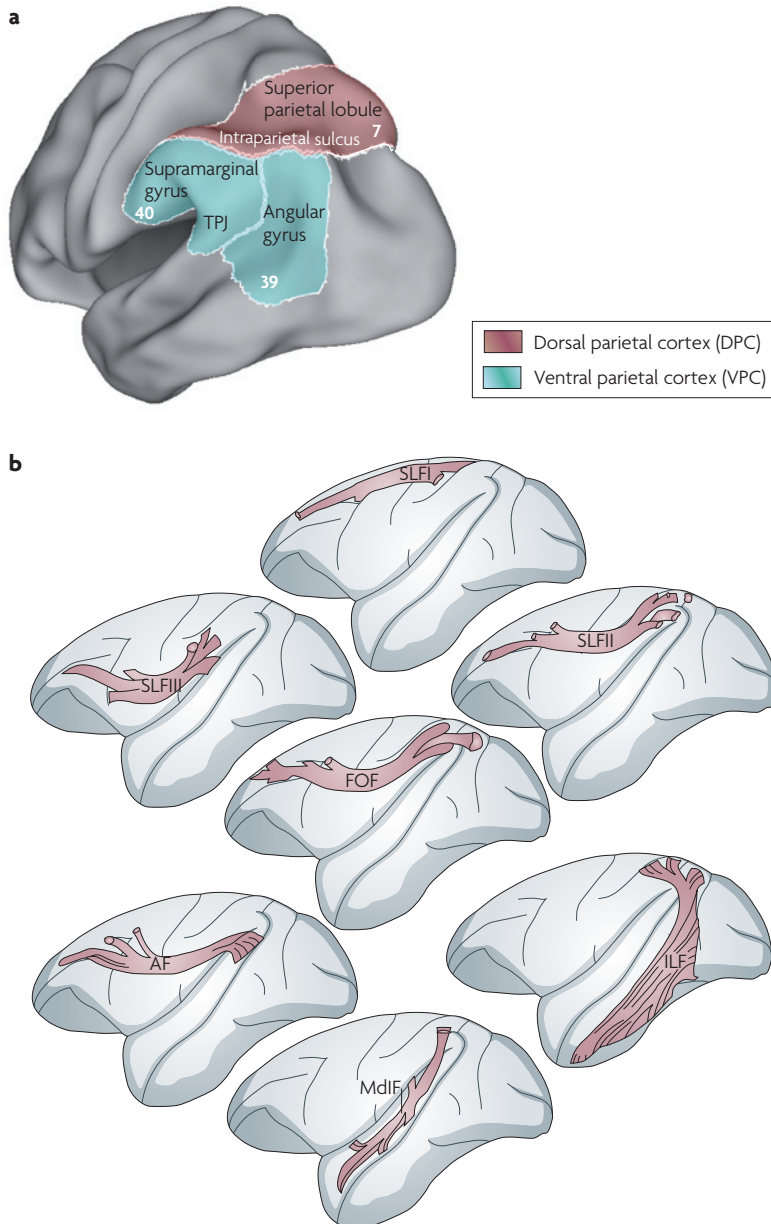


Figure 1 | Subdivisions and connectivity of the posterior parietal cortex. a | The posterior parietal cortex can be divided into the dorsal parietal cortex (DPC) and the ventral parietal cortex (VPC). The DPC comprises the lateral cortex including and superior to the intraparietal sulcus and the medial parietal cortex (the precuneus (not shown)) and largely corresponds to Brodmann area 7. The VPC includes the supramarginal gyrus and the angular gyrus and largely corresponds to Brodmann areas 39 and 40. **b** | The parietal cortex has direct anatomical connections with many brain regions. It is connected to the frontal lobes through the superior longitudinal fasciculi (SLFI, SLFII and SLFIII), the fronto-occipital fasciculus (FOF) and the arcuate fasciculus (AF). The parietal cortex is also connected to the temporal lobes through the middle longitudinal fasciculus (MdIF) and the inferior longitudinal fasciculus (ILF). TPJ, temporoparietal junction. Part **b** modified, with permission, from REF. 12 © (2007) Oxford University Press.

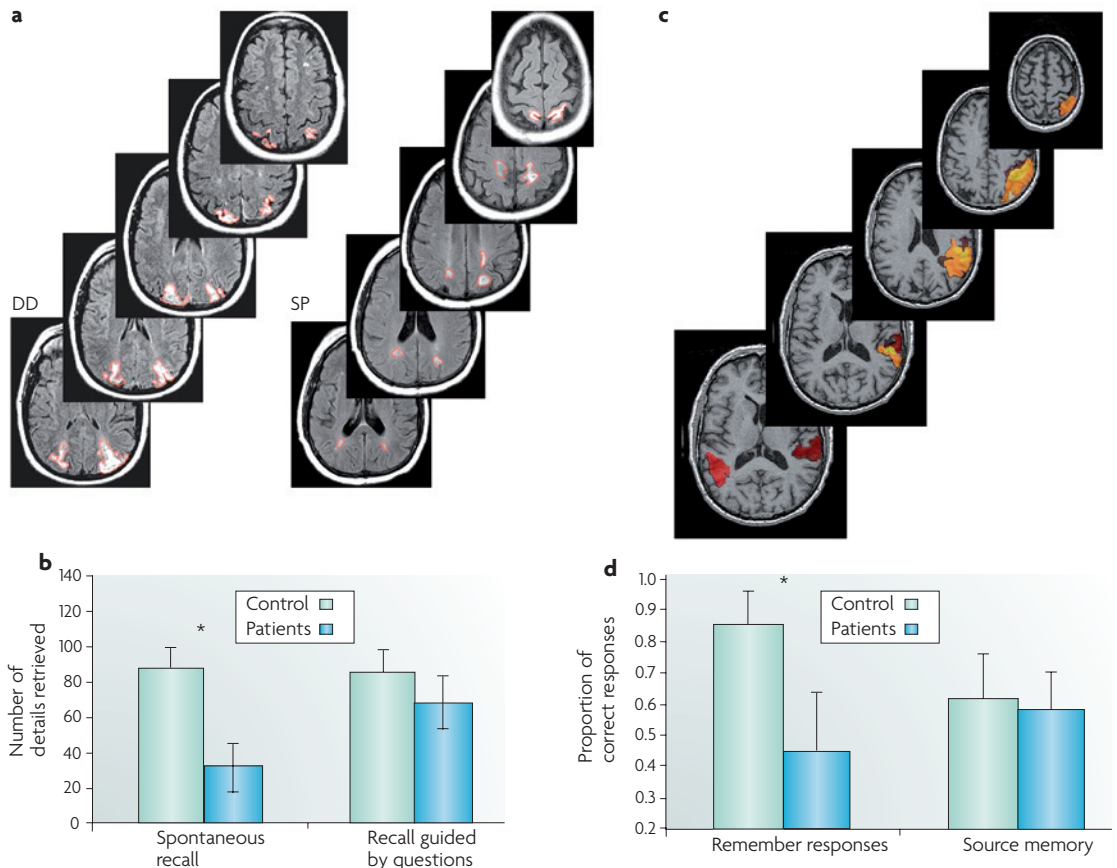


Figure 2 | Parietal lesions and episodic memory. **a,b** | Autobiographical memory was investigated in two patients with bilateral posterior parietal lesions, which were larger in the ventral parietal cortex (VPC) than in the dorsal parietal cortex³⁴. MRI images show the lesions outlined in red (**a**). Participants were impaired when they freely recalled events from their lifetime in as much detail as possible, but not when they answered specific questions about the recalled memories (**b**). **c,d** | Recognition and source memory were compared in patients with left and right VPC lesions³⁵. The brain slices in part **c** show the overlap of the lesions. Patients were impaired in recollection but not in source memory (**d**). In parts **b** and **d**, asterisks indicate significance. Part **a** modified, with permission, from REF. 34 © (2007) Society for Neuroscience. Part **b** modified, with permission, from REF. 35 © (2008) Pergamon Press.

Event-related fMRI

A type of fMRI study in which neural activity during specific trial types is extracted and averaged to allow researchers to contrast trials associated with different behavioural responses, such as successful versus unsuccessful retrieval trials.

Hemispatial neglect

A lesion-induced neurological disorder that is characterized by impaired awareness of the contralesional side of the external world, one's own body and even internal representations.

Balint's syndrome

A neurological syndrome, caused by bilateral damage to the posterior parietal and lateral occipital cortices, that has three hallmark symptoms: simultanagnosia, optic ataxia and oculomotor apraxia.

Retrograde amnesia

The loss of or inability to remember information that was previously stored in long-term memory.

Anterograde amnesia

The inability to store new information in long-term memory.

Autobiographical memory

Memory for one's personal past, such as memory for one's birthday party.

Source memory

Memory for the context in which an item or event was previously encountered.

Item-recognition memory

Memory that allows us to decide whether an item (such as a word) was previously encountered.

recognition and source memory in patients with parietal damage (relative to the normal controls), indicating that the patients were objectively able to access some aspects of the encoding context. However, relative to the controls, patients were reluctant to classify their memories as having been recollected, suggesting that retrieval of contextual details did not trigger remembering states in these patients (FIG. 2d). One patient, SM, commented that although she was able to objectively remember things in real life, she always lacked confidence in her memories, as if she did not know where they had come from.

This evidence of impaired memory after parietal lobe damage must be tempered by several negative findings. In the study described above³⁵, unilateral parietal lobe damage was found to have no effect on source memory. In a similar vein, source memory was assessed in a group of patients whose unilateral parietal lobe lesions overlapped with regions that were found to be activated by a source-memory task and stimuli in an fMRI study³⁷. Again, the patients and controls had similar levels of source-memory accuracy. Preliminary evidence shows

that this finding cannot be attributed to compensation from the intact parietal lobe, because patients with bilateral parietal lobe damage also exhibit intact source memory, regardless of whether they are tested with verbal or visual stimuli (I.R.O., unpublished observations). Also, patients with parietal lesions might describe some autobiographical memories as being recollected when they are allowed to select the memories by themselves. Even then, however, memories that are unique to the event are not as detailed as those of controls, suggesting that simple, subjective assessment of recollection might not be a sensitive enough measure when applied to complex and extended autobiographical events³⁵. There is also evidence that parietal lobe dysfunction has no effect on item-recognition memory. One study found no impairment in recognition of words, pictures and sounds in patients with left parietal lesions, and only a slight deficit in picture recognition in patients with right parietal lesions, which may have been attributable to extra-parietal damage³⁸. Likewise, another group reported that recognition memory was unaffected by

Transcranial magnetic stimulation

(TMS). A technique in which a strong magnetic field is applied to the scalp to disrupt the function of a cortical area on the other side of the cranium. If ongoing cognitive performance is impaired, the affected cortical area can be assumed to be necessary for the task.

Mental imagery

The visualization of images 'in the mind's eye' in the absence of a stimulus.

Hits

Correctly recognized old items in a recognition-memory test.

Correct rejections

Correctly recognized new items in a recognition-memory test.

Signal-detection models of recognition memory

Models that assume that items in a recognition-memory test vary in memory strength (the degree of certainty that the items were previously encountered). Although memory strength is on average greater for old items than for new items, the two distributions overlap. When memory strength exceeds a certain criterion the item is classified as old; otherwise it is classified as new.

temporary disruption of the intraparietal sulcus by application of transcranial magnetic stimulation (TMS) to this region during memory retrieval³⁹.

In summary, a review of the available data indicates that parietal lobe damage in some instances causes episodic-memory impairments. It should be noted that there have only been a small number of studies on this topic and that future research might bring different evidence to bear on it. The deficits are most apparent when there is poor retrieval support. Thus, when patients with parietal lobe damage try to remember complex events, the events' contextual details do not spring to mind automatically³⁴ and do not trigger vivid remembering states³⁵. In tasks with better retrieval support, however, performance is normal: if appropriately questioned, patients can access item information^{35,38}, source information^{35,37} and even multiple contextual features of complex events normally³⁴. It is tempting to conclude that the observed deficits point to a general problem in top-down control. Indeed, memory deficits in patients with frontal-lobe damage have been described in a similar vein, explaining these patients' proclivity to false-alarm and to insert non-stimulus materials into recollected memories. However, neither of these problems is evident in patients with damage to the posterior parietal cortex³⁴, suggesting that an alternative hypothesis must be sought.

Parietal activations during episodic retrieval

As noted above, the parietal cortex is one of the regions that is most frequently activated during episodic-memory retrieval². The prominence of these activations was noted first in ERP studies¹ and then in early PET studies⁴⁰⁻⁴², but theoretical debates focused more on the role of the precuneus in mental imagery^{43,44} than on the contributions of lateral parietal regions, which were considered mainly in relation to contextual memory for spatial⁴⁵ and temporal⁴⁶ information. Interest in the contributions of lateral parietal regions grew rapidly with the publication of the first crop of event-related fMRI studies of recognition memory, which typically compared neural activity for hits versus that for correct rejections⁴⁷⁻⁴⁹. The resulting 'retrieval-success' activations were frequently found in the lateral parietal cortex (FIG. 3a). Retrieval-success activations fit well with the results of ERP studies of recognition memory, which typically find that, compared with correct rejections, hits are associated with positive potentials over parietal scalp regions approximately 300–600 ms post-stimulus¹. Interestingly, as recognition performance increases, retrieval-success activations in the left parietal cortex tend to become more ventral (FIG. 3b). In addition to retrieval-success activations, event-related fMRI studies identified several other activation patterns in the parietal cortex. For example, a group of studies found that certain parietal regions showed 'recollection-related' activations — that is, greater activity for recollection than for familiarity^{50,51}.

Although retrieval-success and recollection-related activation patterns (FIG. 3c) suggest that parietal regions are directly involved in the recovery of episodic information, other activation patterns challenge this idea. First,

a group of studies found that certain parietal regions showed a pattern that is known as 'perceived oldness' (FIG. 3c), whereby activity is greater for items that are classified as 'old' than for items that are classified as 'new', regardless of whether these responses are correct or incorrect^{52,53}. This pattern suggests that parietal activity reflects a judgement that an item is old, rather than the actual recovery of accurate information about the item. Second, another group of studies reported parietal activations showing a pattern that is known as 'recollective orienting' (FIG. 3c), whereby parietal activity is greater for source-memory tasks (that is, those that ask 'where, when and how?') than for item-memory tasks (those that ask 'what?'), independent of the accuracy of the responses⁵⁴⁻⁵⁶. This finding suggests that parietal activity reflects the attempt to recollect information, rather than recollection *per se*. These patterns challenge the idea that parietal regions are involved in retrieval success and recollection.

The parietal cortex and memory hypotheses

Three different hypotheses were proposed to account for the different parietal activation patterns that were observed in the neuroimaging studies⁵⁷. As illustrated in TABLE 1, each of these hypotheses can account for some but not all of the available functional-neuroimaging evidence. The output-buffer hypothesis⁵⁷ postulates that parietal regions contribute to holding retrieved information in a form that is accessible to decision-making processes, similar to the working-memory buffers that were proposed by Baddeley⁵⁸. In other words, parietal regions are assumed to help hold the qualitative content of retrieved information (such as mental images). The strongest support for this hypothesis is provided by the recollection-related activations, because the retrieval of qualitative content is, by definition, greater for recollection than for familiarity. However, the output-buffer hypothesis cannot easily explain the perceived-oldness and recollective-orienting patterns, as one would expect that activity that is associated with the recovery of memory contents should be greater for correct than for incorrect trials.

The mnemonic-accumulator hypothesis⁵⁷ posits that parietal regions do not help to hold actual memories but instead temporally integrate a memory-strength signal to summarize information coming from other brain regions. Depending on whether the accumulated signal is above or below a criterion, 'old' or 'new' recognition judgements are made, as described by signal-detection models of recognition memory⁵⁷. The strongest support for the mnemonic-accumulator hypothesis is provided by perceived-oldness activations, because the accumulation of an oldness signal would lead to an 'old' response, regardless of the accuracy of the signal. This hypothesis can account for recollection-related activations under the assumption that recollected items are perceived as being older than familiar items. However, this hypothesis cannot easily account for the recollective-orienting pattern of findings, which shows that parietal activations can be associated with the intentions of the rememberer rather than with the type of memory decision.

Finally, the attention to internal representation hypothesis⁵⁷ states that parietal regions shift attention to, or maintain attention on, internally generated mnemonic representations. The strongest support for this hypothesis is provided by recollective-orienting activations, which suggests that parietal regions track the intention to remember (that is, they direct voluntary attention to memory contents). However, voluntary attention cannot explain retrieval-success, recollection-related and

perceived-oldness activations, because the attempt to remember information is constant across the different conditions that are compared in these studies.

Although several authors have suggested that dorsal and ventral parietal regions have distinct roles in episodic retrieval^{57,59–61}, none of the three hypotheses makes an explicit distinction between these regions. We believe that this distinction is crucial if we are to understand the contribution of the parietal lobes to episodic memory.

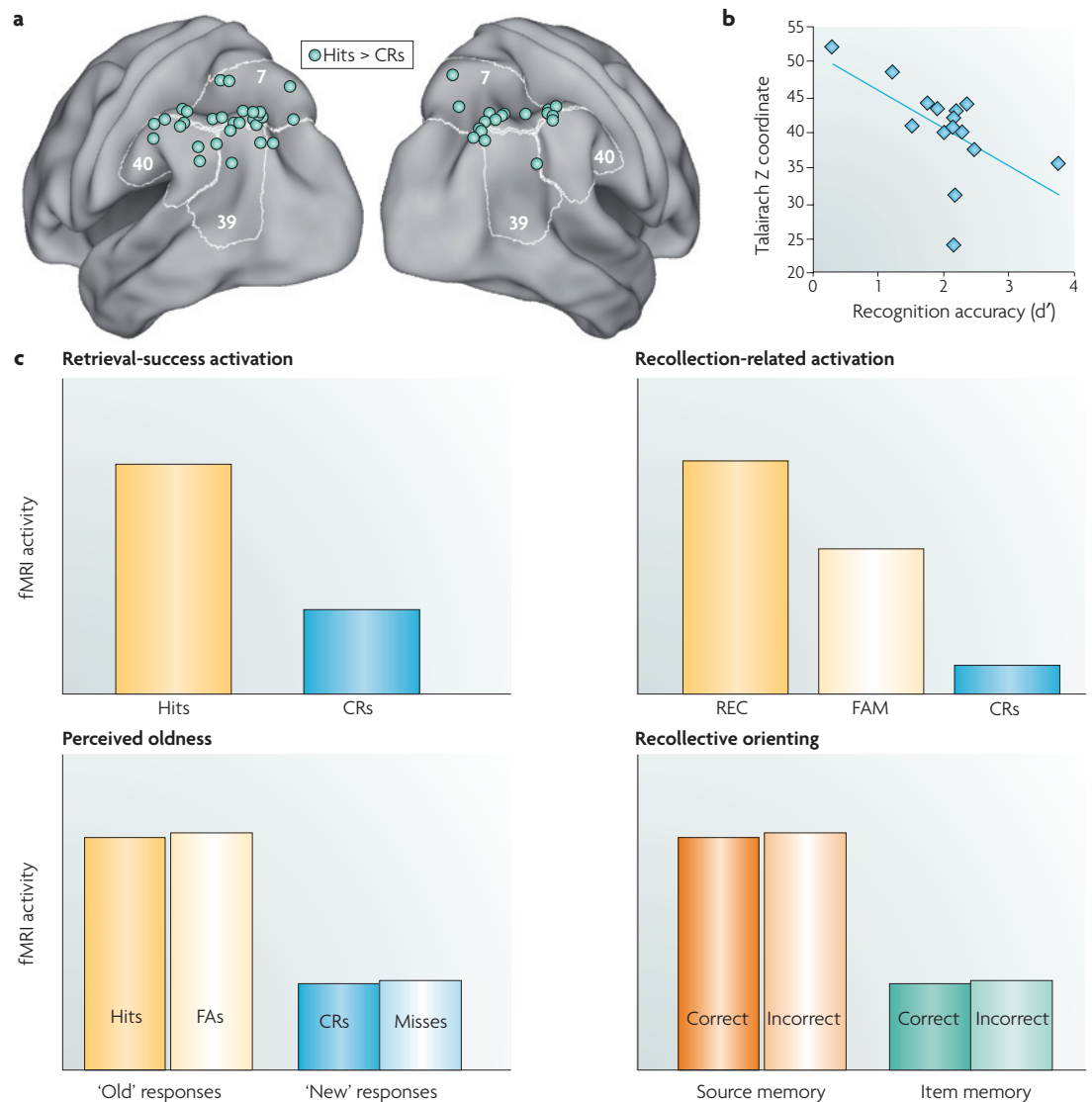


Figure 3 | Parietal activation patterns during episodic-memory tasks. **a** | Retrieval-success activations in the parietal cortex^{46,50,51,94–107} (for a full list of studies and coordinates, see [Supplementary information S1 \(table\)](#)). Event-related functional MRI (fMRI) studies that compare hits to correct rejections (CRs) typically find activations in posterior parietal regions, including both the dorsal parietal cortex (DPC) and the ventral parietal cortex (VPC). **b** | Retrieval-success activation in left parietal regions tends to become more ventral (indicated by a smaller Talairach Z coordinate) as a function of recognition accuracy (d')^{46,50,51,94–100,103–107} (for a full list of studies and coordinates, see [Supplementary information S2 \(table\)](#)). This finding is consistent with the attention to memory (AtoM) model. **c** | Simulated data that illustrate retrieval activation patterns. Retrieval-success activity in the parietal cortex is defined as greater activity for hits than for CRs. Recollection-related activity is defined as greater activity for trials associated with recollection than for trials associated with familiarity (for example, greater activity for 'remember' than for 'know' trials in the remember-know paradigm¹⁰⁸). Perceived oldness is defined as greater activity for items classified as 'old' than for items classified as 'new', regardless of whether these responses are correct or incorrect^{52,53}. Recollective orienting is defined as greater activity for source-memory tasks than for item-memory tasks, independent of the accuracy of the responses^{54–56}.

Table 1 | **Data and theory regarding parietal lobe involvement in episodic memory**

Evidence (with representative studies)	Hypothesis			
	OBH	MAH	AIRH	AtoM
Parietal lesions				
VPC lesions impair spontaneous but not prompted autobiographical recall ³⁴	–	–	–	+++
VPC lesions impair the conscious experience of recollection ³⁵	+++	–	–	+++
Parietal lesions do not impair episodic-memory tests with few response alternatives, including source memory ^{35,37}	–	–	+	+
Parietal activation patterns				
Retrieval-success activations (hit > CR) ^{47–49}	+	+	–	+
Recollection-related activations ^{50,51}	+++	+	–	+++ if VPC
Perceived-oldness activations ^{52,53}	–	+++	–	+
Recollective-orienting activations ^{54–56}	–	–	+++	+++ if DPC
Dorsal versus ventral parietal activations				
Recollection is associated with the VPC; familiarity is associated with the DPC ^{60,61}	+++	–	–	+++
High-confidence recognition is associated with the VPC; low-confidence recognition is associated with the DPC ^{63,64}	+++	–	–	+++

The left-hand column presents various findings; the right-hand columns show how well the four hypotheses that have been put forward to explain the relationship between the parietal lobe and episodic memory can explain these findings. The + symbols represent degree of fit, with more symbols representing a better fit. – represents a poor fit. The AtoM model can account for retrieval-success activations under the assumption that hit versus correct rejection (CR) and old versus new contrasts are confounded by differences in top-down or bottom-up attention. AIRH, attention to internal representations hypothesis; AtoM, attention to memory model; CR, correct rejections; DPC, dorsal parietal cortex; MAH, mnemonic-accumulator hypothesis; OBH, output-buffer hypothesis; VPC, ventral parietal cortex.

A functional dissociation between these regions was observed in studies that compared recollection with familiarity. For example, VPC activity was found to be greater for items that participants classified as recollected than for items that they classified as familiar, whereas DPC activity showed the opposite pattern⁶⁰ (FIG. 4a). In this study the recollection-related VPC activation was in the supramarginal gyrus, but in other studies these activations extend posteriorly towards the angular gyrus⁶² and anteriorly towards the temporoparietal junction⁶¹. Another kind of ventral–dorsal dissociation was found in studies that compared high- and low-confidence recognition responses^{63,64}. For instance, VPC activity was reported to be greater for high- than for low-confidence hits, whereas the converse was true for DPC activity⁶³ (FIG. 4b).

To investigate the consistency of these dissociations, we can compare, across studies, recollection-associated activations with familiarity-associated activations, and activations that are associated with high-confidence decisions with those that are associated with low-confidence decisions. As illustrated by FIG. 4c, with a few exceptions, familiarity and low-confidence activations tend to be more frequent in the DPC (BA 7), whereas recollection and high-confidence activations tend to more frequent in the VPC (BAs 39 and 40). The former activations occur mainly in or above the IPS, whereas the latter occur mainly in the angular and supramarginal gyri that extend into the temporoparietal junction. These data converge with the results of other meta-analyses^{39,65} in supporting the idea that the DPC

and the VPC have different roles in episodic-memory retrieval. However, to clarify the specific contribution of these two regions to episodic retrieval, one must identify a cognitive process that is shared by familiarity and low-confidence recognition and one that is shared by recollection and high-confidence recognition. To identify these processes, it helps to take a brief detour outside the episodic-memory domain and consider the role of parietal regions in attention.

Parietal cortex and attention

As noted above, attention is one of the cognitive functions that is traditionally associated with posterior parietal regions²⁶. Several of the cognitive deficits that are associated with parietal lobe lesions, including neglect and simultanagnosia, can be described as attention deficits. Recent evidence suggests that the DPC and the VPC have different roles in attention. A recent attention model proposes that the DPC together with dorsal frontal regions is associated with top-down attention, whereas the VPC together with ventral frontal regions is associated with bottom-up attention²³. The dorsal attention system is involved in “preparing and applying goal-directed selection for stimuli and responses”, whereas the ventral attention system is involved in the “detection of behaviourally relevant stimuli, particularly when they are salient and unexpected” (REF. 23).

The notion that the DPC and the VPC have different roles in attention is supported by functional-neuroimaging and lesion evidence²³. For example, one fMRI study that used a visual search paradigm found that DPC activity

Top-down attention

Attention that is guided by goals.

Bottom-up attention

This term is usually used to describe attention that is guided by incoming sensory information. According to the AtoM model, attention can be driven by incoming information regardless of whether the information comes from the senses or from memory.

Visual search paradigm

An attention task that requires participants to find a target (such as the letter F) hidden among distractors (such as many instances of the letter E).

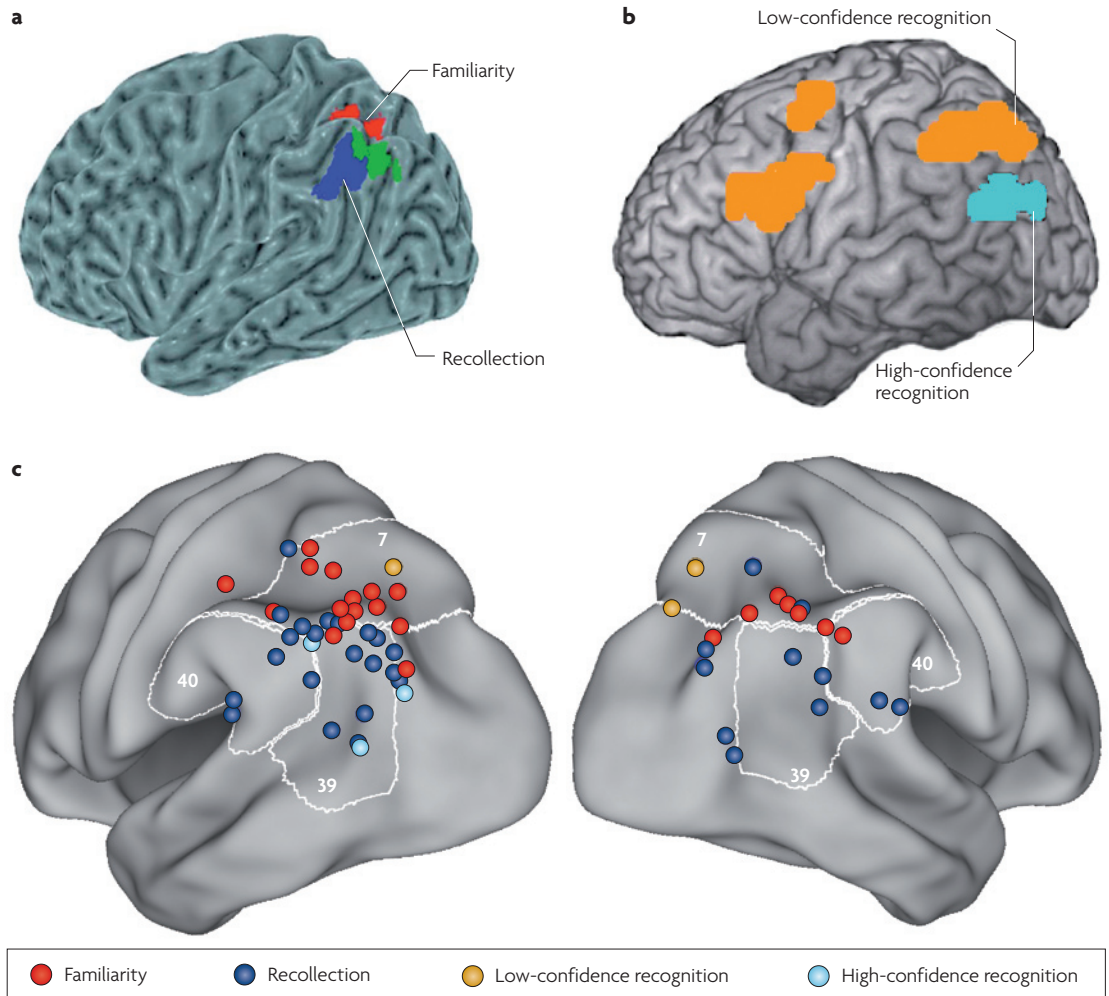


Figure 4 | Ventral–dorsal dissociations in activity. **a** | In a functional MRI (fMRI) study of the remember–know paradigm⁶⁰, the ventral parietal cortex (VPC) showed greater activity for remember than for know trials, whereas the dorsal parietal cortex (DPC) showed the opposite pattern. **b** | In an fMRI study of confidence during recognition memory⁶³, the VPC showed greater activity for high- than for low-confidence hits, whereas the DPC showed the opposite pattern. **c** | A meta-analysis of parietal activity during episodic retrieval. The images plot the peaks of activations in two kinds of event-related fMRI studies (for a list of studies and coordinates, see [Supplementary information S3 \(table\)](#) and [S4 \(table\)](#)). A first group of peaks (red and dark blue dots) is from studies that identified activity related to recollection or familiarity by using the remember–know paradigm, by distinguishing successful from unsuccessful source-memory retrieval, or by comparing the retrieval of items encoded under deep versus shallow study tasks^{48,49,51,58,59,96,100–102,109–118}. A second group of peaks (yellow and pale blue dots) is from studies that investigated recognition confidence^{61,62,81,119}. In general, recollection and high-confidence recognition were associated with VPC activations, whereas familiarity and low-confidence recognition were associated with DPC activations. Part **a** modified, with permission, from REF. 60 © (2006) American Physiological Society. Part **b** modified, with permission, from REF. 63 © (2007) Pergamon Press.

began as soon as the search instructions were given and continued throughout the search period, whereas VPC activity was greater than DPC activity when the target was detected⁶⁶. Thus, DPC activity mediates preparatory top-down attention, whereas VPC activity is associated with the capture of bottom-up attention by behaviourally relevant stimuli. Activity that is associated with bottom-up attention can also be captured using unexpected (spatial and non-spatial) stimuli^{67–72}. When a relevant stimulus that was out of the current attentional focus appears, the VPC sends a ‘circuit breaker’ signal to the DPC, which shifts attention to the previously unattended

stimulus⁷³. The right VPC is also the most frequent location of lesions that cause neglect, which can be described as a deficit in bottom-up attention: patients with neglect can voluntarily direct attention to the contralateral side and can use cognitive cues to anchor attention to the left visual space, but they have a deficit in detecting stimuli that are outside the focus of ongoing processing²³.

Parietal cortex, attention and episodic memory
 Could the distribution of episodic-retrieval activations in FIG. 4c be associated with the allocation of top-down and bottom-up attention to memory by the DPC and the

VPC, respectively? The main problem with this theory seems to be that bottom-up attention is typically defined as attention that is driven by sensory stimuli (that is, 'exogenous attention'), whereas memory retrieval is primarily concerned with internally generated information. However, if one defines bottom-up attention as attention that is driven by incoming information from any source, then it is clear that bottom-up attention has an important role in episodic memory. The most obvious example of bottom-up attention that is driven by episodic memory is involuntary remembering, as in the case of the Proustian character who experienced an outpouring of autobiographical memories after tasting a tea-soaked madeleine. However, the phenomenon of memory-guided bottom-up attention is not limited to involuntary personal memories: it occurs whenever an interesting memory enters consciousness and takes over attentional resources.

Thus, extending the distinction between top-down and bottom-up attention to the episodic-memory domain, we propose that the DPC is associated with the

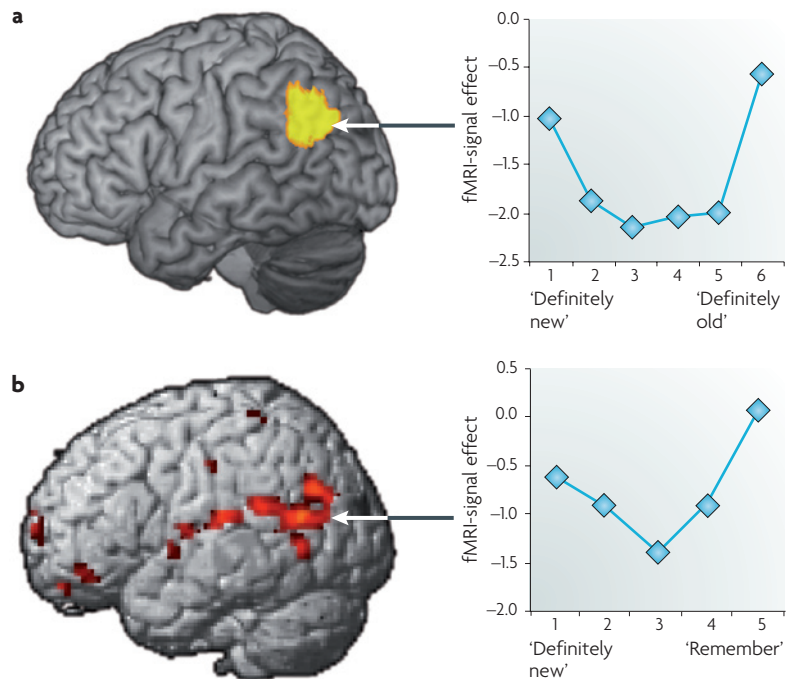
allocation of attentional resources to memory retrieval according to the goals of the rememberer (top-down attention), whereas the VPC is associated with the capture of attentional resources by relevant memory cues and/or recovered memories (bottom-up attention)^{3,4}. We call this idea the attention to memory (AtoM) model. According to this model, DPC activity maintains retrieval goals, which modulate memory-related activity in the MTL, whereas VPC activity, like a circuit breaker, signals the need for a change in the locus of attention following the detection of relevant memories that have been retrieved by the MTL. Relevant memories include not only the realization that an event is old, but also the certainty that an event is new (see BOX 1). Because VPC activity reflects the attentional adjustments that are triggered by the products of ongoing MTL activity, it fluctuates continuously over time, as illustrated by FIG. 5. According to the AtoM model, the VPC detects relevant information generated by the MTL but does not hold or accumulate this information (as the output-buffer and mnemonic-accumulator hypotheses propose).

Box 1 | Ventral parietal cortex: bottom-up attention or episodic buffer?

A recent version of the output-buffer hypothesis proposes that the ventral parietal cortex (VPC) is the site of the 'episodic buffer' (REF. 59), a component of Baddeley's working-memory model⁶⁴ that is specialized for maintaining integrated multi-modal information. Both this hypothesis and the attention to memory (AtoM) model can explain why VPC activity during episodic retrieval tends to increase as a function of recollection and confidence. According to the episodic-buffer hypothesis, recollected and high-confidence trials involve the retrieval of greater amounts of integrated multi-modal information, which must be maintained by the episodic buffer. According to the AtoM model, these trials are more likely to capture bottom-up attentional resources and enter consciousness. Both hypotheses can account

equally well for the evidence that VPC lesions impair recollection³⁵. However, the episodic-buffer model cannot explain why VPC lesions impair spontaneous but not prompted autobiographical recall³⁴ or source memory^{35,37}. If the VPC is the site of the episodic buffer, one would expect that VPC damage should impair episodic memory in all conditions.

The AtoM model can also explain the finding that VPC activity shows greater activity for both 'definitely old' and 'definitely new' items than it does for low-confidence recognition responses, as shown in the figure. To account for these findings, the episodic-buffer hypothesis would need to postulate a recall-to-reject strategy, in which the correct item is first recalled and then compared with the incorrect target⁶¹. Such a strategy is unlikely during item recognition⁸⁵. By contrast, the AtoM model can accommodate strong VPC responses to both definitely new and definitely old trials, because these are the trials that are most relevant to the test and, hence, that are most likely to capture bottom-up attention. Part **a** modified, with permission, from REF. 62 © (2006) American Physiological Society. Part **b** modified, with permission, from REF. 61 © (2005) Society for Neuroscience.



The AtoM model therefore proposes that the roles of the DPC and the VPC in episodic retrieval are largely the same as their respective roles in attention. Bottom-up capture of attention by memory occurs when information that is relevant to the current task is retrieved. On the other hand, top-down attention to memory is necessary when the memory decision is effortful (see ‘indirect retrieval’ in BOX 2) and therefore attention-demanding pre- and post-retrieval processing is needed to emit the memory judgement. Thus, the AtoM model can explain why the VPC and the DPC are differentially involved in high- and low-confidence recognition as well as recollection and familiarity (FIG. 4). High-confidence hits tend to occur when lots of information is rapidly retrieved from memory; this is likely to capture attention bottom-up and engage the VPC. By contrast, low-confidence hits tend to occur when recovery is poor and thus an effortful memory search and top-down attention processes that engage the DPC are required. Similar ideas explain the differential involvement of the VPC and the DPC in recollection and familiarity. Recollection involves the spontaneous retrieval of episodic details, which capture bottom-up attentional resources and engage the VPC, whereas familiarity involves more difficult decisions that are more dependent on top-down control and DPC functions. Given that recollection increases with accuracy, the AtoM model is also consistent with the data in FIG. 3b. The AtoM model can also explain why a study that directly compared an episodic-retrieval task with a top-down attention task found overlaps in the DPC but not in the VPC⁷⁴.

Top-down attention and bottom-up attention are two separate dimensions, rather than the different endpoints of a single dimension. As illustrated by the phenomenon of involuntary memory, memory detection can occur independently of whether it was preceded by the deployment of top-down attention to memory. Conversely, top-down attention to memory can be triggered even after memory detection has happened, if the retrieved memory does not satisfy some criteria. Thus, even if in some situations increased top-down attention seems to be correlated with decreased bottom-up attention (for example, in low-confidence hits), or vice versa, top-down and bottom-up attention to memory are independent processes.

The AtoM model predicts that top-down and bottom-up attention processing interact closely during episodic retrieval (FIG. 5), just as they do during perception. In a typical retrieval situation, the intention to remember (for example thinking: Where did I park the car?) initiates a memory search that is guided by top-down attentional processes that are mediated by the DPC, and the recovered memories (such as an image of the car in the north end of the parking lot) grab bottom-up attentional resources that are mediated by the VPC. However, because of their close interaction, the distinction between the attentional functions of the DPC and those of the VPC is graded rather than sharp. First, because the VPC responds only to relevant stimuli, it is indirectly sensitive to the behavioural goals that determine the relevancy of stimuli. fMRI studies of attention have shown that the VPC does not respond to all salient stimuli, but only to those that share modality⁶⁸ or other

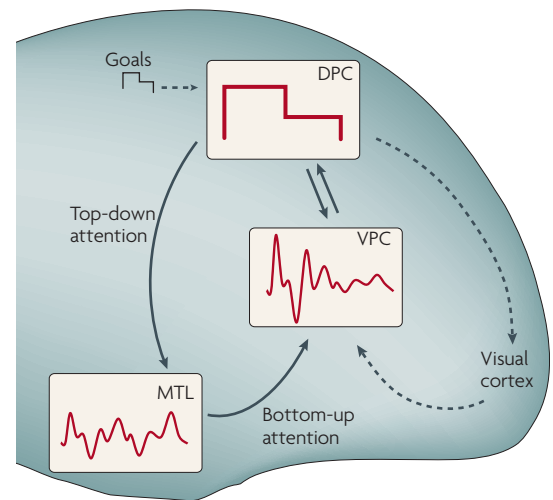


Figure 5 | A simple graphical description of the attention to memory (AtoM) model. Activity in the ventral parietal cortex (VPC) fluctuates continuously, tracking changes in medial temporal lobe (MTL) activity, which in turn reflects the recovery of episodic memories. By contrast, activity in the dorsal parietal cortex (DPC) reflects top-down attentional processes that are guided by retrieval goals. For example, an earlier segment of the incoming signal might be more relevant to behavioural goals than a later segment. The DPC and the VPC interact closely: the goals that are maintained by the DPC define which targets are relevant, and the targets that are detected by the VPC can alter or change behavioural goals. The attentional processes that the VPC and the DPC contribute to episodic retrieval are the same attentional processes that these regions contribute to perception (for example, visual attention (dashed arrows)). Figure modified, with permission, from REF. 3 © (2008) Pergamon Press.

perceptual features⁷⁵ with the target. Likewise, while they are searching memory for a parking location, VPC-mediated bottom-up attentional resources are more likely to be captured by spatial images than by memories of words or sounds. Second, because the goals that are processed by the DPC are constantly updated, the DPC is indirectly sensitive to target detection. fMRI studies of attention have shown that DPC activity starts while the target is being searched for but falls off soon after the target is detected⁷⁶. In the case of memory, one would also expect that success or failure in detecting the target leads to a change in the goals that are being processed by the DPC. Thus, because the DPC and the VPC interact closely, one is more likely to find graded differences than sharp dissociations between the contributions of these regions to episodic retrieval.

Because the AtoM model postulates that the role of the parietal cortex in episodic memory is related to attention, it can explain why inferior-parietal lesions do not yield dramatic episodic-memory deficits but, instead, produce subtle effects under certain conditions. In general, attention enhances cognitive processes but is not essential for them: when attention fails, cognitive operations are weakened but they are not completely

Box 2 | Attention and direct versus indirect episodic retrieval

It might be surprising to learn that distraction has a much less detrimental effect on memory retrieval than it does on encoding. To understand this finding, it is necessary to distinguish between direct and indirect retrieval^{86,87}. During direct retrieval, a cue interacts automatically with information that is stored in memory. Direct retrieval is mediated by the medial temporal lobe (MTL) and requires few attentional resources. By contrast, during indirect retrieval the target memory is not automatically elicited by the cue: it has to be recovered through a strategic search process. Indirect retrieval is mediated by the prefrontal cortex and is attentionally demanding. Accordingly, indirect retrieval is impaired by the performance of a concurrent task^{88–90}, whereas direct retrieval is not. Nevertheless, direct retrieval does inflict costs on the distracting task^{91,92}, suggesting that, even when it is mandatory, episodic-memory retrieval usurps attentional resources from ongoing processes.

According to the attention to memory (AtoM) model, indirect retrieval depends on top-down attention mediated by the dorsal parietal cortex (DPC), which is connected to prefrontal cortex regions that control attention and strategic retrieval⁹³. Consequently, directing attention away from the memory task will impair the neural mechanisms that are needed for strategic retrieval. By contrast, direct retrieval depends on bottom-up attention processes mediated by the ventral parietal cortex (VPC), which has strong links to the MTL²². Judging from the behavioural results, the MTL seems to have privileged access to the VPC, such that attention is directed away from salient events in the environment during direct retrieval. Why that should be the case is not known. Perhaps once a retrieval mode is entered, the system is set so that the VPC is biased to favour information from the MTL instead of information from posterior neocortical structures involved in perception. Alternatively, it might be that the brain is organized so that connections from the MTL to the VPC are stronger than connections from perceptual structures to the VPC, and thus that they always compete effectively against them. Resolution of these issues awaits results from behavioural, neuroimaging and lesion studies.

obliterated. In the case of vision, for example, attention deficits can produce neglect but they do not normally lead to blindness³². For the same reason, the effect of attention deficits on episodic memory should not be expected to yield amnesia. Thus, the AtoM model can explain why parietal lesions do not yield reliable deficits in episodic-retrieval tests that provide specific probes about to-be-remembered stimuli^{37–39}. By contrast, significant episodic-retrieval deficits are more likely to occur in open-ended tasks, such as spontaneous recall of autobiographical events³⁴ or the introspective evaluation of recovered memories³⁵. Currently, the number of studies on the effects of parietal lesions is too small to reach definite conclusions.

If the contributions of parietal regions to episodic retrieval are attributed to their role in attention, then the effects of parietal damage on episodic memory should resemble the neglect syndrome. This hypothetical syndrome could be called memory neglect³. The characteristics of memory neglect can be inferred from the characteristics of visual neglect, with the exception of differences between left and right hemi-space, which are not part of our memory-neglect concept. Patients with visual neglect typically have VPC damage and show a deficit in bottom-up attention: they have a deficit in detecting stimuli spontaneously but can voluntarily direct attention to stimuli in the neglected hemifield²³. By analogy, the AtoM model predicts that VPC lesions should yield a memory-neglect deficit whereby patients cannot spontaneously report relevant details in retrieved memories (bottom-up attention) but can access these

details if guided by specific questions (top-down attention). This is exactly what was found³⁴: patients who had mostly VPC damage were impaired in spontaneous autobiographical recall but were normal when asked specific questions about their memories (FIG. 2b). In other words, the patients' memories are intact but they do not capture bottom-up attention by themselves. This idea can also explain how patients with VPC damage have preserved source memory and yet recollection deficits³⁵ (FIG. 2d): contextual details of encoding are available to patients but do not appear spontaneously at retrieval and therefore cannot inform remember decisions. An alternative interpretation of these findings is that patients with VPC damage have difficulty in retrieving multiple details of memory simultaneously, a deficit that could be termed memory simultanagnosia. This can explain why parietal lesions sometimes do not impair episodic retrieval in tasks that focus participants' attention on a single dimension of the stimuli^{34,37}. Distinguishing between memory neglect and memory simultanagnosia will require specifically designed studies, but both ideas are consistent with the AtoM model because both assume that the essential mnemonic deficit after VPC damage is in bottom-up attention to internal representations.

Open questions

Although the available evidence supports the idea that the contributions of parietal regions to episodic retrieval can be explained by the distinction between top-down and bottom-up attentional processes, there are many open questions for future research. One group of questions involves left–right and anterior–posterior distribution of activation in episodic-retrieval and attention fMRI studies. VPC activations related to bottom-up attention tend to be stronger in the left hemisphere in episodic-retrieval studies⁵⁹, but stronger in the right hemisphere in perceptual-attention studies²³. This is not a serious problem for the AtoM model because perceptual-attention studies often find bilateral VPC activations^{67–71}. Because episodic-retrieval studies tend to use meaningful verbal stimuli, whereas attention studies tend to use meaningless perceptual materials, it is possible that lateralization differences reflect differences in stimuli⁷⁷ rather than in processes. Regarding anterior–posterior distribution, VPC activations in episodic-retrieval studies often extend posteriorly towards the angular gyrus⁵⁹, whereas in perceptual-attention studies they often extend anteriorly and ventrally towards the superior temporal gyrus (that is, the temporoparietal junction)²³. However, there are several examples of episodic-retrieval activations in the anterior VPC^{50,61} and attention activations in the posterior VPC^{66,78,79}, and the two distributions show substantial overlap in the supramarginal gyrus. Thus, further research on the localization of parietal activations during episodic-retrieval and perceptual-attention tasks is warranted.

Another open question is the relation between parietal and frontal regions. According to the model of attentional systems described above²³, the top-down attention system involves not only the DPC but also dorsal frontal regions, and the bottom-up attention

Memory neglect

A hypothetical syndrome in which sufferers have a deficient ability to spontaneously detect details in retrieved memories (impaired bottom-up attention) but a preserved ability to search and find these details when guided by specific goals (spared top-down attention).

Memory simultanagnosia

A hypothetical syndrome associated with a difficulty in retrieving multiple details of memory simultaneously.

system involves not only the VPC but also ventral frontal regions. Could this also be the case for episodic retrieval? It is not difficult to find examples supporting this idea. In the data shown in FIG. 4b, dorsolateral prefrontal cortex activity was greater for low- than for high-confidence recognition hits⁶³. The involvement of the dorsolateral prefrontal cortex in low-confidence recognition has also been found in other fMRI studies^{80,81}. Although the model of attentional systems links top-down attention to the frontal eye fields, rather than to the dorsolateral prefrontal cortex, it is possible that the dorsolateral prefrontal cortex plays a more important part for non-spatial stimuli. Turning to bottom-up attention, several fMRI studies have reported activations in ventrolateral prefrontal cortex regions as a function of the amount of information recovered from episodic and semantic memory^{82,83}. As should be apparent, the literature on prefrontal cortex activity during episodic retrieval is large and complex, and reviewing it is beyond the scope of this article. A reasonable conclusion at this point is that it is not implausible that the AtoM model could be extended to include frontal regions.

Summary

The posterior parietal cortex has long been known to be crucial for attention during perception and mental representation of location, but it was rarely, if ever, implicated

in memory retrieval. The advent of functional neuroimaging, however, showed clearly that the posterior parietal cortex is often activated during memory retrieval. In this paper we have reviewed this evidence and argued that the pattern of parietal activation that is observed during memory retrieval parallels its role in directing attention during perception. Just as the superior parietal cortex is involved in the voluntary allocation of attention during perception, so it is also associated with top-down (voluntary) processes that support retrieval search, monitoring and verification. By contrast, the inferior parietal cortex is activated when the output of such processes leads to a clear, unambiguous outcome, as occurs in recollection. This is similar to the inferior-parietal activation that is associated with the exogenous capture of attention by a salient stimulus in perception. The findings in the few studies that have been carried out on memory retrieval in people with parietal lobe lesions are consistent with these observations. On this basis, we have proposed a dual-process model of attention to memory (AtoM), assigning different roles to the superior and inferior parietal cortex. Other models have also been proposed; each, including our own, has limitations. The emergence of these models will stimulate investigation and lead not only to a better understanding of how attention and memory interact, but also, it is hoped, to a unified theory of attention that is applicable to all domains.

- Rugg, M. D. in *The Cognitive Neurosciences* (ed. Gazzaniga, M. S.) 789–801 (MIT Press, Cambridge, Massachusetts, 1995).
- Cabeza, R. & Nyberg, L. Imaging cognition II: an empirical review of 275 PET and fMRI studies. *J. Cogn. Neurosci.* **12**, 1–47 (2000).
- Cabeza, R. Role of posterior parietal regions in episodic memory retrieval: the dual attentional processes hypothesis. *Neuropsychologia* **46**, 1813–1827 (2008).
- Ciaramelli, E., Grady, C. L. & Moscovitch, M. Top-down and bottom-up attention to memory: a hypothesis (AtoM) on the role of the posterior parietal cortex in memory retrieval. *Neuropsychologia* **46**, 1828–1851 (2008).
- Rudge, P. & Warrington, E. K. Selective impairment of memory and visual perception in splenial tumours. *Brain* **114**, 349–360 (1991).
- Valenstein, E. *et al.* Retrosplenial amnesia. *Brain* **110**, 1631–1646 (1987).
- von Cramon, D. Y. & Schuri, U. The septo-hippocampal pathway in rhesus monkey: II. Evidence for segregated corticocortical networks linking sensory and limbic areas with the frontal lobe. *J. Comp. Neurol.* **287**, 422–445 (1989).
- Lewis, J. W. & van Essen, D. C. Corticocortical connections of visual, sensorimotor, and multimodal processing areas in the parietal lobe of the macaque monkey. *J. Comp. Neurol.* **428**, 112–137 (2000).
- Petrides, M. & Pandya, D. N. Projections to the frontal cortex from the posterior parietal region in the rhesus monkey. *J. Comp. Neurol.* **228**, 105–116 (1984).
- Petrides, M. & Pandya, D. N. Dorsolateral prefrontal cortex: comparative cytoarchitectonic analysis in the human and the macaque brain and corticocortical connection patterns. *Eur. J. Neurosci.* **11**, 1011–1036 (1999).
- Schmahmann, J. D. *et al.* Association fibre pathways of the brain: parallel observations from diffusion spectrum imaging and autoradiography. *Brain* **130**, 630–653 (2007).
- Kobayashi, Y. & Amaral, D. G. Macaque monkey retrosplenial cortex: II. Cortical afferents. *J. Comp. Neurol.* **466**, 48–79 (2003).
- Morris, R., Pandya, D. N. & Petrides, M. Fiber system linking the mid-dorsolateral frontal cortex with the retrosplenial/presubular region in the rhesus monkey. *J. Comp. Neurol.* **407**, 183–192 (1999).
- Blatt, G. J., Pandya, D. N. & Rosene, D. L. Parcellation of cortical afferents to three distinct sectors in the parahippocampal gyrus of the rhesus monkey: an anatomical and neurophysiological study. *J. Comp. Neurol.* **466**, 161–179 (2003).
- Clover, D. M., West, R. A., Lynch, J. C. & Strick, P. L. The inferior parietal lobule is the target of output from the superior colliculus, hippocampus, and cerebellum. *J. Neurosci.* **21**, 6283–6291 (2001).
- Insausti, R. & Munoz, M. Cortical projections of the non-entorhinal hippocampal formation in the cynomolgus monkey (*Macaca fascicularis*). *Eur. J. Neurosci.* **14**, 435–451 (2001).
- Lavenex, P., Suzuki, W. A. & Amaral, D. G. Perirhinal and parahippocampal cortices of the macaque monkey: projections to the neocortex. *J. Comp. Neurol.* **447**, 394–420 (2002).
- Munoz, M. & Insausti, R. Cortical efferents of the entorhinal cortex and the adjacent parahippocampal region in the monkey (*Macaca fascicularis*). *Eur. J. Neurosci.* **22**, 1368–1388 (2005).
- Rockland, K. S. & Van Hoesen, G. W. Some temporal and parietal cortical connections converge in CA1 of the primate hippocampus. *Cereb. Cortex* **9**, 232–237 (1999).
- Suzuki, W. A. & Amaral, D. G. Perirhinal and parahippocampal cortices of the macaque monkey: cortical afferents. *J. Comp. Neurol.* **350**, 497–533 (1994).
- Vincent, J. L. *et al.* Coherent spontaneous activity identifies a hippocampal-parietal memory network. *J. Neurophysiol.* **96**, 3517–3531 (2006).
- Corbetta, M. & Shulman, G. L. Control of goal-directed and stimulus-driven attention in the brain. *Neural Rev. Neurosci.* **3**, 201–215 (2002).
This article introduces an influential cognitive-neuroscience model of attention that distinguishes between a dorsal frontoparietal system that mediates top-down attention and a ventral frontoparietal system that mediates bottom-up attention. The AtoM model proposed in this article extends the dorsal-ventral distinction in the parietal cortex to the episodic retrieval domain.
- Milner, A. D. & Goodale, M. A. *The Visual Brain in Action* (Oxford Univ. Press, New York, 1995).
- Mishkin, M., Ungerleider, L. G. & Macko, K. A. Object vision and spatial vision: two cortical pathways. *Trends Neurosci.* **6**, 414–417 (1983).
- Posner, M. I. & Petersen, S. E. The attention system of the human brain. *Annu. Rev. Neurosci.* **13**, 25–42 (1990).
- Bisiach, E. & Luzzatti, C. Unilateral neglect of representational space. *Cortex* **14**, 129–133 (1978).
- Danckert, J. & Ferber, S. Revisiting unilateral neglect. *Neuropsychologia* **44**, 987–1006 (2006).
- Driver, J. & Vuilleumier, P. Perceptual awareness and its loss in unilateral neglect and extinction. *Cognition* **79**, 39–88 (2001).
- Vallar, G. Spatial hemineglect in humans. *Trends Cogn. Sci.* **2**, 87–97 (1998).
- Pavani, F., Ladavas, E. & Driver, J. Auditory and multisensory aspects of visuospatial neglect. *Trends Cogn. Sci.* **7**, 407–414 (2003).
- Driver, J. & Mattingley, J. B. Parietal neglect and visual awareness. *Nature Neurosci.* **1**, 17–22 (1998).
- Critchley, M. *The Parietal Lobes* (Arnold, London, 1953).
- Berryhill, M. E., Phuong, L., Picasso, L., Cabeza, R. & Olson, I. R. Parietal lobe and episodic memory: bilateral damage causes impaired free recall of autobiographical memory. *J. Neurosci.* **27**, 14415–14423 (2007).
This study reported the first evidence of significant deficits in episodic-memory retrieval following parietal lesions. Consistent with the AtoM model, patients with bilateral ventral parietal lesions showed a deficit in spontaneously reporting details in their autobiographical memories but could provide these details when probed.
- Davidson, P. S. R. *et al.* Does lateral parietal cortex support episodic memory? Evidence from focal lesion patients. *Neuropsychologia* **46**, 1745–1755 (2008).
This study demonstrated that patients with unilateral parietal lesions show deficits in experiencing recollection, even when they show normal source-memory performance when tested with specific probes. This pattern is consistent with the AtoM model.

36. Yonelinas, A. P. The nature of recollection and familiarity: a review of 50 years of research. *J. Mem. Lang.* **46**, 441–517 (2002).
37. Simons, J. S. *et al.* Is the parietal lobe necessary for recollection in humans? *Neuropsychologia* **46**, 1185–1191 (2008). **This study showed that unilateral parietal lesions, which overlap with regions that are activated during source-memory tasks, do not significantly impair source-memory performance.**
38. Haramati, S., Soroker, N., Dudai, Y. & Levy, D. A. The posterior parietal cortex in recognition memory: a neuropsychological study. *Neuropsychologia* **46**, 1756–1766 (2008). **This study investigated patients with lesions that included the parietal cortex. Patients with left-hemisphere lesions were not impaired in recognition memory for words, pictures and sounds.**
39. Rossi, S. *et al.* Prefrontal and parietal cortex in human episodic memory: an interference study by repetitive transcranial magnetic stimulation. *Eur. J. Neurosci.* **23**, 793–800 (2006). **This study did not find a significant effect of TMS stimulation on episodic-retrieval performance.**
40. Kapur, S. *et al.* Functional role of the prefrontal cortex in retrieval of memories: a PET study. *Neuroreport* **6**, 1880–1884 (1995).
41. Tulving, E. *et al.* Neuroanatomical correlates of retrieval in episodic memory: auditory sentence recognition. *Proc. Natl Acad. Sci. USA* **91**, 2012–2015 (1994).
42. Schacter, D. L., Alpert, N. M., Savage, C. R., Rauch, S. L. & Albert, M. S. Conscious recollection and the human hippocampal formation: evidence from positron emission tomography. *Proc. Natl Acad. Sci. USA* **93**, 321–325 (1996).
43. Fletcher, P. C. *et al.* The mind's eye—precuneus activation in memory related imagery. *Neuroimage* **2**, 195–200 (1995).
44. Buckner, R. L., Raichle, M. E., Miezin, F. M. & Petersen, S. E. PET studies of the recall of pictures and words from memory. *Abstr. Soc. Neurosci.* **21**, 1441 (1995).
45. Moscovitch, M., Kapur, S., Köhler, S. & Houle, S. Distinct neural correlates of visual long-term memory for spatial location and object identity: a positron emission tomography (PET) study in humans. *Proc. Natl Acad. Sci. USA* **92**, 3721–3725 (1995).
46. Cabeza, R. *et al.* Brain regions differentially involved in remembering what and when: a PET study. *Neuron* **19**, 863–870 (1997).
47. Buckner, R. L. *et al.* Functional-anatomic study of episodic retrieval. II. Selective averaging of event-related fMRI trials to test the retrieval success hypothesis. *Neuroimage* **7**, 163–175 (1998).
48. Konishi, S., Wheeler, M. E., Donaldson, D. I. & Buckner, R. L. Neural correlates of episodic retrieval success. *Neuroimage* **12**, 276–286 (2000).
49. Rugg, M. D. & Henson, R. N. A. in *The Cognitive Neuroscience of Memory Encoding and Retrieval* (eds Parker, A. E., Wilding, E. L. & Bussey, T.) 3–37 (Psychology Press, Hove, 2002).
50. Eldridge, L. L., Knowlton, B. J., Furlanski, C. S., Bookheimer, S. Y. & Engle, S. A. Remembering episodes: a selective role for the hippocampus during retrieval. *Nature Neurosci.* **3**, 1149–1152 (2000).
51. Henson, R. N. A., Rugg, M. D., Shallice, T., Josephs, O. & Dolan, R. J. Recollection and familiarity in recognition memory: an event-related functional magnetic resonance imaging study. *J. Neurosci.* **19**, 3962–3972 (1999).
52. Wheeler, M. A. & Buckner, R. L. Functional dissociation among components of remembering: control, perceived oldness, and content. *J. Neurosci.* **23**, 3869–3880 (2003). **This article introduced the perceived-oldness hypothesis of parietal contributions to episodic retrieval.**
53. Kahn, I., Davachi, L. & Wagner, A. D. Functional-neuroanatomic correlates of recollection: implications for models of recognition memory. *J. Neurosci.* **24**, 4172–4180 (2004).
54. Dobbins, I. G., Foley, H., Schacter, D. L. & Wagner, A. D. Executive control during episodic retrieval: multiple prefrontal processes subserve source memory. *Neuron* **35**, 989–996 (2002).
55. Dobbins, I. G., Rice, H. J., Wagner, A. D. & Schacter, D. L. Memory orientation and success: separable neurocognitive components underlying episodic recognition. *Neuropsychologia* **41**, 318–333 (2003).
56. Dobbins, I. G. & Wagner, A. D. Domain-general and domain-sensitive prefrontal mechanisms for recollecting events and detecting novelty. *Cereb. Cortex* **15**, 1768–1778 (2005).
57. Wagner, A., Shannon, B., Kahn, I. & Buckner, R. Parietal lobe contributions to episodic memory retrieval. *Trends Cogn. Sci.* **9**, 445–453 (2005). **This article reviews fMRI evidence of and theoretical accounts about the role of the parietal cortex in episodic retrieval.**
58. Baddeley, A. Working memory: looking back and looking forward. *Nature Rev. Neurosci.* **4**, 829–839 (2003).
59. Vilberg, K. L. & Rugg, M. D. Memory retrieval and the parietal cortex: a review of evidence from event-related fMRI. *Neuropsychologia* **46**, 1787–1799 (2008). **This article includes a meta-analysis of fMRI activations during episodic retrieval and attributes the role of the ventral parietal cortex to a working-memory module known as the episodic buffer.**
60. Wheeler, M. E. & Buckner, R. L. Functional-anatomic correlates of remembering and knowing. *Neuroimage* **21**, 1337–1349 (2004). **Using the remember-know paradigm, this fMRI study demonstrated that recollection engages ventral parietal regions, whereas familiarity engages more dorsal parietal regions.**
61. Yonelinas, A. P., Otten, L. J., Shaw, K. N. & Rugg, M. D. Separating the brain regions involved in recollection and familiarity in recognition memory. *J. Neurosci.* **25**, 3002–3008 (2005).
62. Daselaar, S. M., Fleck, M. S. & Cabeza, R. E. Triple dissociation in the medial temporal lobes: recollection, familiarity, and novelty. *J. Neurophysiol.* **96**, 1902–1911 (2006).
63. Kim, H. & Cabeza, R. Trusting our memories: dissociating the neural correlates of confidence in veridical vs. illusory memories. *J. Neurosci.* **27**, 12190–12197 (2007).
64. Moritz, S., Glascher, J., Sommer, T., Buchel, C. & Braus, D. F. Neural correlates of memory confidence. *Neuroimage* **33**, 1188–1193 (2006).
65. Skinner, E. L. & Fernandes, M. A. Neural correlates of recollection and familiarity: a review of neuroimaging and patient data. *Neuropsychologia* **45**, 2163–2179 (2007).
66. Corbetta, M., Kincade, J. M., Ollinger, J. M., McAvoy, M. P. & Shulman, G. L. Voluntary orienting is dissociated from target detection in human posterior parietal cortex. *Nature Neurosci.* **3**, 292–297 (2000).
67. Clark, V. P., Fannon, S., Lai, S., Benson, R. & Bauer, L. Responses to rare visual target and distractor stimuli using event-related fMRI. *J. Neurophysiol.* **83**, 3133–3139 (2000).
68. Downar, J., Crawley, A. P., Mikulis, D. J. & Davis, K. D. A multimodal cortical network for the detection of changes in the sensory environment. *Nature Neurosci.* **3**, 277–283 (2000).
69. Downar, J., Crawley, A. P., Mikulis, D. J. & Davis, K. D. The effect of task relevance on the cortical response to changes in visual and auditory stimuli: an event-related fMRI study. *Neuroimage* **14**, 1256–1267 (2001).
70. Kiehl, K. A., Laursen, K. R., Duty, T. L., Forster, B. B. & Liddle, P. F. Neural sources involved in auditory target detection and novelty processing: an event-related fMRI study. *Psychophysiology* **38**, 133–142 (2001).
71. Marois, R., Leung, H. C. & Gore, J. C. A stimulus-driven approach to object identity and location processing in the human brain. *Neuron* **25**, 717–728 (2000).
72. Braver, T. S., Barch, D. M., Gray, J. R., Molfese, D. L. & Snyder, A. Anterior cingulate cortex and response conflict: effects of frequency, inhibition and errors. *Cereb. Cortex* **11**, 825–836 (2001).
73. Corbetta, M., Patel, G. & Shulman, G. L. The reorienting system of the human brain: from environment to theory of mind. *Neuron* **58**, 306–324 (2008).
74. Cabeza, R. *et al.* Attention-related activity during episodic memory retrieval: a cross-function fMRI study. *Neuropsychologia* **41**, 390–399 (2003).
75. Serences, J. T. *et al.* Coordination of voluntary and stimulus-driven attentional control in human cortex. *Psychol. Sci.* **16**, 114–122 (2005).
76. Shulman, G. L., Ollinger, J. M., Linenweber, M., Petersen, S. E. & Corbetta, M. Multiple neural correlates of detection in the human brain. *Proc. Natl Acad. Sci. USA* **98**, 313–318 (2001).
77. Milner, B. Interhemispheric differences in the localization of psychological processes in man. *Br. Med. Bull.* **27**, 272–277 (1971).
78. Arrington, C. M., Carr, T. H., Mayer, A. R. & Rao, S. M. Neural mechanisms of visual attention: object-based selection of a region in space. *J. Cogn. Neurosci.* **12**, 106–117 (2000).
79. Kincade, J. M., Abrams, R. A., Astafiev, S. V., Shulman, G. L. & Corbetta, M. An event-related functional magnetic resonance imaging study of voluntary and stimulus-driven orienting of attention. *J. Neurosci.* **25**, 4593–4604 (2005).
80. Henson, R. N. A., Rugg, M. D., Shallice, T. & Dolan, R. J. Confidence in recognition memory for words: dissociating right prefrontal roles in episodic retrieval. *J. Cogn. Neurosci.* **12**, 913–923 (2000).
81. Fleck, M. S., Daselaar, S. M., Dobbins, I. G. & Cabeza, R. Role of prefrontal and anterior cingulate regions in decision-making processes shared by memory and nonmemory tasks. *Cereb. Cortex* **16**, 1623–1630 (2006).
82. Prince, S. E., Tsukiura, T., Daselaar, S. M. & Cabeza, R. Distinguishing the neural correlates of episodic memory encoding and semantic memory retrieval. *Psychol. Sci.* **18**, 144–151 (2007).
83. Thompson-Schill, S. L., D'Esposito, M., Aguirre, G. K. & Farah, M. J. Role of left inferior prefrontal cortex in retrieval of semantic knowledge: a reevaluation. *Proc. Natl Acad. Sci. USA* **94**, 14792–14797 (1997).
84. Baddeley, A. The episodic buffer: a new component of working memory? *Trends Cogn. Sci.* **4**, 417–425 (2000).
85. Rotello, C. M. & Heit, E. Two-process models of recognition memory: evidence for recall-to-reject? *J. Mem. Lang.* **40**, 432–453 (1999).
86. Moscovitch, M. Memory and working-with-memory: a component process model based on modules and central systems. *J. Cogn. Neurosci.* **4**, 257–267 (1992).
87. Moscovitch, M. in *Memory Systems* (eds Schacter, D. L. & Tulving, E.) 269–310 (MIT Press, Cambridge, Massachusetts, 1994).
88. Jacoby, L. L., Woloshyn, V. & Kelley, C. M. Becoming famous without being recognized: unconscious influences of memory produced by divided attention. *J. Exp. Psychol. Gen.* **118**, 115–125 (1989).
89. Kane, M. J. & Engle, R. W. Working-memory capacity, proactive interference, and divided attention: limits on long-term memory retrieval. *J. Exp. Psychol. Learn. Mem. Cogn.* **26**, 336–358 (2000).
90. Moscovitch, M. Cognitive resources and dual-task interference effects at retrieval in normal people: the role of the frontal lobes and medial temporal cortex. *Neuropsychology* **8**, 524–534 (1994).
91. Craik, F. I. M., Govoni, R., Naveh-Benjamin, M. & Anderson, N. D. The effects of divided attention on encoding and retrieval processes in human memory. *J. Exp. Psychol. Gen.* **125**, 159–180 (1996).
92. Fernandes, M. A. & Moscovitch, M. Divided attention and memory: evidence of substantial interference effects at retrieval and encoding. *J. Exp. Psychol. Gen.* **129**, 155–176 (2000).
93. Fox, M. D., Corbetta, M., Snyder, A. Z., Vincent, J. L. & Raichle, M. E. Spontaneous neuronal activity distinguishes human dorsal and ventral attention systems. *Proc. Natl Acad. Sci. USA* **103**, 10046–10051 (2006).
94. Donaldson, D. I., Petersen, S. E. & Buckner, R. L. Dissociating memory retrieval processes using fMRI: evidence that priming does not support recognition memory. *Neuron* **31**, 1047–1059 (2001).
95. Donaldson, D. I., Petersen, S. E., Ollinger, J. M. & Buckner, R. L. Dissociating state and item components of recognition memory using fMRI. *Neuroimage* **13**, 129–142 (2001).
96. Henson, R. N., Hornberger, M. & Rugg, M. D. Further dissociating the processes involved in recognition memory: an fMRI study. *J. Cogn. Neurosci.* **17**, 1058–1073 (2005).
97. Herron, J. E., Henson, R. N. & Rugg, M. D. Probability effects on the neural correlates of retrieval success: an fMRI study. *Neuroimage* **21**, 302–310 (2004).
98. Maratos, E. J., Dolan, R. J., Morris, J. S., Henson, R. N. & Rugg, M. D. Neural activity associated with episodic memory for emotional context. *Neuropsychologia* **39**, 910–920 (2001).
99. McDermott, K. B., Jones, T. C., Petersen, S. E., Lageman, S. K. & Roediger, H. L. Retrieval success is accompanied by enhanced activation in anterior prefrontal cortex during recognition memory: an event-related fMRI study. *J. Cogn. Neurosci.* **12**, 965–976 (2000).
100. Ragland, J. D. *et al.* Event-related fMRI of frontotemporal activity during word encoding and recognition in schizophrenia. *Am. J. Psychiatry* **161**, 1004–1015 (2004).

101. Ragland, J. D., Valdez, J. N., Loughhead, J., Gur, R. C. & Gur, R. E. Functional magnetic resonance imaging of internal source monitoring in schizophrenia: recognition with and without recollection. *Schizophr. Res.* **87**, 160–171 (2006).
102. Shannon, B. J. & Buckner, R. L. Functional-anatomical correlates of memory retrieval that suggest nontraditional processing roles for multiple distinct regions within posterior neocortex. *J. Neurosci.* **24**, 10084–10092 (2004).
103. Tsukiura, T., Mochizuki-Kawai, K. & Fujii, T. The effect of encoding strategies on medial temporal lobe activations during the recognition of words: an event-related fMRI study. *Neuroimage* **25**, 452–461 (2005).
104. von Zerssen, G. C., Mecklinger, A., Opitz, B. & von Cramon, D. J. Conscious recollection and illusory recognition: an event-related fMRI study. *Eur. J. Neurosci.* **13**, 2148–2156 (2001).
105. Leube, D. T., Erb, M., Grodd, W., Bartels, M. & Kircher, T. T. Successful episodic memory retrieval of newly learned faces activates a left fronto-parietal network. *Cogn. Brain Res.* **18**, 97–101 (2003).
106. Leveroni, C. L. *et al.* Neural systems underlying the recognition of familiar and newly learned faces. *J. Neurosci.* **20**, 878–886 (2000).
107. Weis, S., Klaver, P., Reul, J., Elger, C. E. & Fernandez, G. Temporal and cerebellar brain regions that support both declarative memory formation and retrieval. *Cereb. Cortex* **14**, 256–267 (2004).
108. Tulving, E. Memory and consciousness. *Can. Psychol.* **25**, 1–12 (1985).
109. Fenker, D. B., Schott, B. H., Richardson-Klavehn, A., Heinze, H. J. & Duzel, E. Recapitulating emotional context: activation of amygdala, hippocampus and fusiform cortex during recollection and familiarity. *Eur. J. Neurosci.* **21**, 1993–1999 (2005).
110. Montaldi, D., Spencer, T. J., Roberts, N. & Mayes, A. R. The neural system that mediates familiarity memory. *Hippocampus* **16**, 504–520 (2006).
111. Johnson, J. D. & Rugg, M. D. Recollection and the reinstatement of encoding-related cortical activity. *Cereb. Cortex* **17**, 2507–2515 (2007).
112. Vilberg, K. L. & Rugg, M. D. Dissociation of the neural correlates of recognition memory according to familiarity, recollection, and amount of recollected information. *Neuropsychologia* **45**, 2216–2225 (2007).
113. Woodruff, C. C., Johnson, J. D., Uncapher, M. R. & Rugg, M. D. Content-specificity of the neural correlates of recollection. *Neuropsychologia* **43**, 1022–1032 (2005).
114. Sharot, T., Delgado, M. R. & Phelps, E. A. How emotion enhances the feeling of remembering. *Nature Neurosci.* **7**, 1376–1380 (2004).
115. Cansino, S., Marquet, P., Dolan, R. J. & Rugg, M. D. Brain activity underlying encoding and retrieval of source memory. *Cereb. Cortex* **12**, 1048–1056 (2002).
116. Kensinger, E. A. & Schacter, D. L. Neural processes underlying memory attribution on a reality-monitoring task. *Cereb. Cortex* **16**, 1126–1133 (2006).
117. Iidaka, T., Matsumoto, A., Nogawa, J., Yamamoto, Y. & Sadato, N. Frontoparietal network involved in successful retrieval from episodic memory. Spatial and temporal analyses using fMRI and ERP. *Cereb. Cortex* **16**, 1349–1360 (2006).
118. Daselaar, S. M., Fleck, M. S., Dobbins, I. G., Madden, D. J. & Cabeza, R. Effects of healthy aging on hippocampal and rhinal memory functions: an event-related fMRI study. *Cereb. Cortex* **16**, 1771–1782 (2006).
119. Chua, E. F., Schacter, D. L., Rand-Giovannetti, E. & Sperling, R. A. Understanding metamemory: neural correlates of the cognitive process and subjective level of confidence in recognition memory. *Neuroimage* **29**, 1150–1160 (2006).

Acknowledgements

This work was supported by US National Institutes of Health (NIH) grants AG1971 and AG2770 to R.C., National Sciences and Engineering Council of Canada grant A8347 and Canadian Institutes of Health Research grant MGP 6694 to M.M., NIH grant MH071615 to I.O., and an EU Marie Curie individual fellowship to EC. We thank J. Kragel for help with image construction, and P. Davidson and B. Levine for helpful discussions.

FURTHER INFORMATION

Roberto Cabeza's homepage: www.cabezalab.org
 Elisa Ciaramelli's homepage: www.psych.utoronto.ca/Neuropsychologylab/elisa.html
 Ingrid Olsen's homepage: www.temple.edu/cnl/
 Morris Moscovitch's homepage: www.psych.utoronto.ca/Neuropsychologylab

SUPPLEMENTARY INFORMATION

See online article: [S1 \(table\)](#) | [S2 \(table\)](#) | [S3 \(table\)](#) | [S4 \(table\)](#)

ALL LINKS ARE ACTIVE IN THE ONLINE PDF